

GAIN – Kick Off Meeting

MICM AI LAB Presentation


Chest X-Ray Images Classification

Georgian Artificial Intelligence Networking and Twinning Initiative
Project #101078950
HORIZON EUROPE - WIDERA-2021-ACCESS-03 (Twinning)
01.10.2022 - 30.09.25

GAIN Chest-X-Ray-Images-Classification


Demo

[Demo video](#)




 **Chest X-Ray classification**

Pick an image to test

Drag and drop file here Limit: 200MB per file Browse files



Cancel Submit

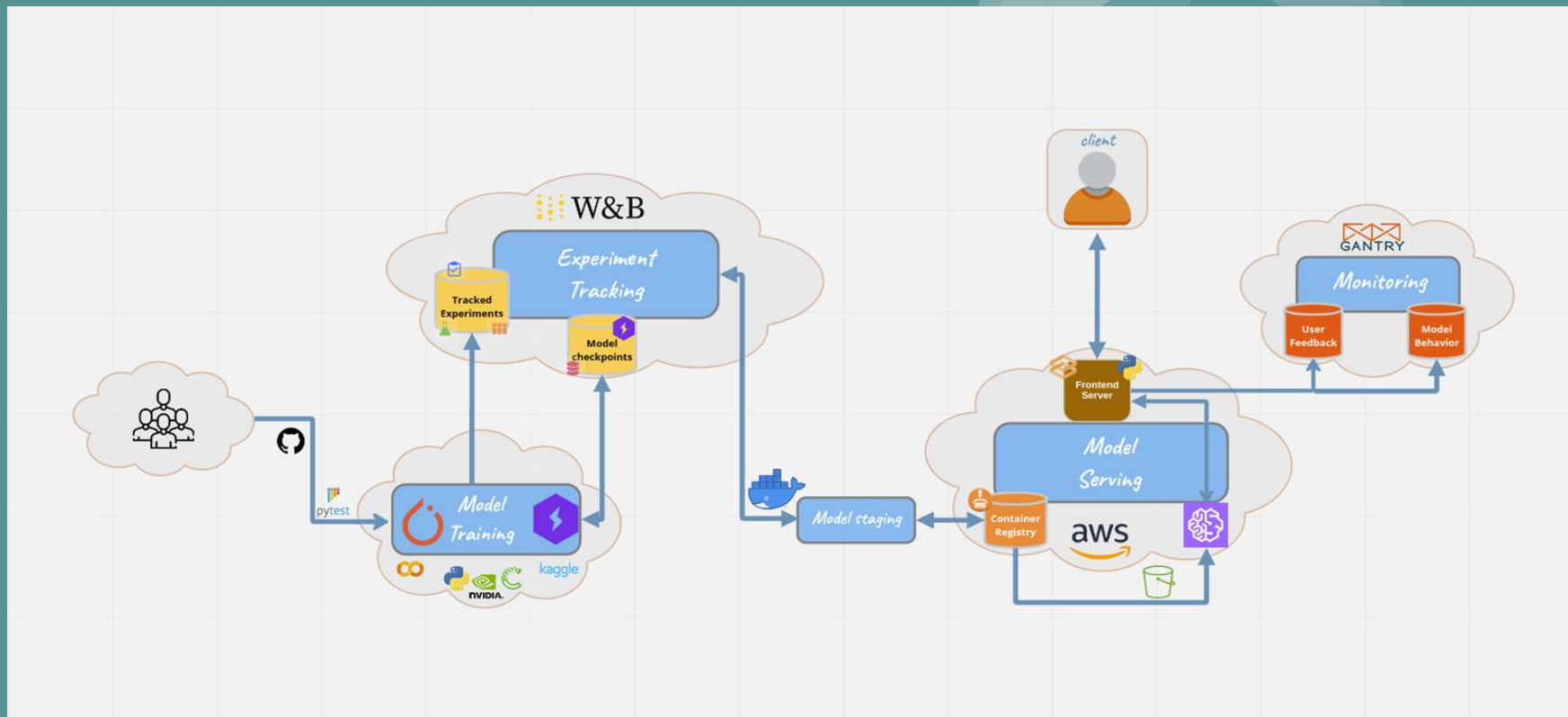
  

Pneumonia

Normal

GAIN Chest-X-Ray-Images-Classification

Workflow

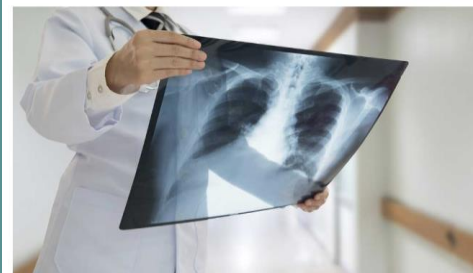

GAIN Chest-X-Ray-Images-Classification

Report

Chest-X-Ray-Images-Classification

RaphaelKalandadze



What is Pneumonia?

Pneumonia is an inflammatory condition of the lung affecting primarily the small air sacs known as alveoli. Symptoms typically include some combination of productive or dry cough, chest pain, fever and difficulty breathing. The severity of the condition is variable. Pneumonia is usually caused by infection with viruses or bacteria and less commonly by other microorganisms, certain medications or conditions such as autoimmune diseases. Risk factors include cystic fibrosis, chronic obstructive pulmonary disease (COPD), asthma, diabetes, heart failure, a history of smoking, a poor ability to cough such as following a stroke and a weak immune system. Diagnosis is often based on symptoms and physical examination. Chest X-ray, blood tests, and culture of the sputum may help confirm the diagnosis. The disease may be classified by where it was acquired, such as community- or hospital-acquired or healthcare-associated pneumonia.

Dataset

This dataset contains 5,856 validated Chest X-Ray images. The images are split into a training set and a testing set of independent patients. Images are labeled as (disease:NORMAL/BACTERIA/VIRUS)-(randomized patient ID)-(image number of a patient).

Chest X-ray images (anterior-posterior) were selected from retrospective cohorts of pediatric patients of one to five years old from Guangzhou Women and Children's Medical Center, Guangzhou. All chest X-ray imaging was performed as part of patients' routine clinical care.

For the analysis of chest x-ray images, all chest radiographs were initially screened for quality control by removing all low quality or unreadable scans. The diagnoses for the images were then graded by two expert physicians before being cleared for training the AI system. In order to account for any grading errors, the evaluation set was also checked by a third expert.

